

# Diagnosis of Very Long Chain Acyl-Dehydrogenase Deficiency From an Infant's Newborn Screening Card

John C. Wood, MD, PhD\*; Mark J. Magera, MA‡; Piero Rinaldo, MD, PhD‡; Margretta Reed Seashore, MDS; Arnold W. Strauss, MD||; and Alan Friedman, MD¶

**ABSTRACT.** Very long chain fatty acid dehydrogenase (VLCAD) deficiency is a rare but treatable cause of cardiomyopathy, fatty liver, skeletal myopathy, pericardial effusions, ventricular arrhythmias, and sudden death. Unrecognized, VLCAD deficiency may be rapidly progressive and fatal, secondary to its cardiac involvement. Because early diagnosis improves outcome, we present a neonate with VLCAD deficiency in whom retrospective analysis of the newborn screening card revealed that a correct diagnosis could have been made by newborn screening using tandem mass spectrometry.

Our patient demonstrated a classic neonatal course with transient hypoglycemia at birth, interpreted as culture-negative sepsis, followed by a quiescent period notable only for hypotonia and poor feeding. At 3 months, he presented with cardiorespiratory failure and pericardial effusions, requiring pericardiocentesis, tracheostomy, and prolonged mechanical ventilation. Plasma free-fatty acid and acylcarnitine profiles demonstrated small but significant elevations of C14:2, C14:1, C16, and C18:1 acylcarnitine species, findings consistent with a biochemical diagnosis of VLCAD deficiency. Enteral feeds were changed to Portagen formula with marked improvement in cardiac symptoms over several weeks.

To confirm the biochemical diagnosis, molecular analysis was performed by analysis of genomic DNA on a blood sample of the patient. Sequencing analysis and delineation of VLCAD mutations were performed using polymerase chain reaction and genomic sequencing. The patient was heterozygous for 2 different disease-causing mutations at the VLCAD locus. The maternal mutation was a deletion of bp 842–3 in exon 8, causing a shift in the reading frame. The paternal mutation was G+1A in the consensus donor splice site after exon 1; this splice-site mutation would likely result in decreased mRNA. The likely consequence of these mutations is essentially a null phenotype.

To determine whether this case could have been picked up by tandem mass spectrometry analysis at birth when the patient was asymptomatic, acylcarnitine anal-

ysis was performed on the patient's original newborn card (after obtaining parental consent, the original specimen was provided courtesy of Dr Kenneth Pass, Director, New York State Newborn Screening Program). The blood sample had been obtained at 1 week of age and stored at room temperature for 6 months and at 70°C thereafter for 18 months. Electrospray tandem mass spectrometry used a LC-MS/MS API 2000 operated in ion evaporation mode with the TurboIonSpray ionization probe source.

The acylcarnitine profile obtained from the patient's original newborn card was analyzed 2 years after it was obtained. In comparison with a normal control, there was a significant accumulation of long chain acylcarnitine species, with a prominent peak of tetradecenoylcarnitine (C14:1), the most characteristic metabolic marker of VLCAD deficiency. This profile would have likely been even more significant if it had been analyzed at the time of collection, yet 2 years later is sufficient to provide strong biochemical evidence of the underlying disorder.

**Discussion.** VLCAD was first discovered in 1992, and clinical experience with VLCAD deficiency has been accumulating rapidly. Indeed, the patients originally diagnosed with long chain acyl-CoA deficiency suffer instead from VLCAD deficiency. The phenotype of VLCAD deficiency is heterogeneous, ranging from catastrophic metabolic and cardiac failure in infancy to mild hypoketotic, hypoglycemia, and exertional rhabdomyolysis in adults. This case demonstrates that VLCAD deficiency could have been detected from the patient's own neonatal heel-stick sample. Most likely, a presymptomatic diagnosis would have avoided at least part of a lengthy and intensive prediagnosis hospitalization that had an estimated cost of \$400 000.

Although VLCAD is relatively rare, timely and correct diagnosis leads to dramatic recovery, so that detection by newborn screening could prevent the onset of arrhythmias, heart failure, metabolic insufficiency, and death. Fatty acid oxidation defects, including VLCAD deficiency, may account for as many as 5% of sudden infant death patients. Recent instrumentation advances have made automated tandem mass spectrometry of routine neonatal heel-stick samples technically feasible. Pilot studies have demonstrated an incidence of fatty acid oxidation defects, including short chain, medium chain, and very long chain acyl-CoA dehydrogenase deficiencies, of approximately 1/12 000. As a result, cost-benefit ratios for this approach should be systematically examined. *Pediatrics* 2001;108(1). URL: <http://www.pediatrics.org/cgi/content/full/108/1/e19>; *cardiomyopathy, very long chain fatty acid dehydrogenase, fatty acid oxidation defects, pericardial effusions, infant, neonatal screening.*

From the \*Division of Cardiology, Department of Pediatrics, University of Southern California School of Medicine, Children's Hospital of Los Angeles, Los Angeles, California; ‡Mayo Clinic, Department of Laboratory Medicine and Pathology, Biochemical Genetics Laboratory, Rochester, Minnesota; §Department of Genetics, Yale School of Medicine, New Haven, Connecticut; ||Department of Pediatrics, Vanderbilt University School of Medicine, Nashville, Tennessee; ¶Section of Pediatric Cardiology, Department of Pediatrics, Yale School of Medicine, New Haven, Connecticut.  
Received for publication Nov 6, 2000; accepted Mar 22, 2001.  
Address correspondence to Dr John Wood, Division of Cardiology, Children's Hospital of Los Angeles, Mailstop 34, 4650 Sunset Blvd, Los Angeles, CA, 90027-0034. E-mail: [jwood@usc.edu](mailto:jwood@usc.edu)  
PEDIATRICS (ISSN 0031 4005). Copyright © 2001 by the American Academy of Pediatrics.

ABBREVIATIONS. VLCAD, very long chain fatty acid dehydrogenase.

Very long chain fatty acid dehydrogenase (VLCAD) deficiency is a rare but treatable cause of cardiomyopathy, fatty liver, skeletal myopathy, pericardial effusions, ventricular arrhythmias, and sudden death.<sup>1-5</sup> Unrecognized, VLCAD deficiency may be rapidly progressive and fatal, secondary to its cardiac involvement.<sup>2,3</sup> Because early diagnosis improves outcome,<sup>5-7</sup> we present a neonate with VLCAD deficiency in whom retrospective analysis of the newborn screening card revealed that a correct diagnosis could have been made by newborn screening using tandem mass spectrometry.

### CASE REPORT

The patient was the full-term male product of a normal pregnancy born by cesarean section for failure to progress. Family history was negative for cardiomyopathy, sudden death, or structural heart disease, and the patient had 1 healthy sibling. After delivery, a 1-week course of empirical intravenous antibiotics was administered because of prolonged rupture of membranes, positive maternal group B streptococcal vaginal cultures, and mild respiratory distress, despite negative blood cultures. At 3 months, neurologic evaluation demonstrated hypotonia, hyporeflexia, hepatomegaly, and poor respiratory effort, and the patient was hospitalized. Within 24 hours, the patient suffered a respiratory arrest requiring intubation and mechanical ventilation. Echocardiogram demonstrated concentric left ventricular hypertrophy with mildly depressed systolic function and a large pericardial effusion. Pericardiocentesis yielded 167 mL of transudative fluid over 72 hours. Because of persistent hypoketotic hypoglycemia, acidosis, elevated liver and muscle enzymes, hepatomegaly, and hypotonia, a presumptive diagnosis of a fatty acid oxidation defect was made. Enteral feeds were initiated with Pregestimil (Mead-Johnson, Evansville, IN), and the patient was transferred to Yale-New Haven Children's Hospital, New Haven, Connecticut.

At admission, the patient was nondysmorphic and well-nourished with a physical examination notable for hepatomegaly, hypotonia, and hyporeflexia; no murmur or gallop was appreciated. Admission laboratory values demonstrated sodium 132, potassium 5.5, chloride 100, bicarbonate 20, glucose 64, serum glutamic-oxalacetic transaminase 159 (0-35 U/L), serum glutamic-pyruvic transaminase 55 (0-35 U/L), alkaline phosphatase 173 (30-130 U/L), creatine kinase 601 (24-195 U/L), and creatine kinase myocardial fraction 62 (<5 ng/mL). Urine analysis demonstrated a specific gravity of 1.015 and was negative for ketones, blood, and protein. Blood and urine cultures were negative. Plasma free-fatty acid and acylcarnitine profiles demonstrated small but significant elevations of C14:2, C14:1, C16, and C18:1 acylcarnitine species,

findings consistent with a biochemical diagnosis of VLCAD deficiency. Enteral feeds were subsequently changed to Portagen formula.

Electrocardiogram demonstrated normal sinus rhythm with a rate of 140 and biventricular hypertrophy. Initial chest radiograph demonstrated cardiomegaly and clear lung fields. Echocardiogram demonstrated marked concentric left ventricular hypertrophy with an interventricular septal thickness of 9 mm and a posterior wall thickness of 7 mm, both well beyond the 95th percentile for body surface area. Shortening fraction and ejection fraction by M-Mode were lower limits of normal for age at 28% and 58%, respectively.

To confirm the biochemical diagnosis, molecular analysis was performed by analysis of genomic DNA on a blood sample of the patient. Sequencing analysis and delineation of VLCAD mutations was performed as previously described, using polymerase chain reaction and genomic sequencing.<sup>3</sup> The patient was heterozygous for 2 different disease-causing mutations at the VLCAD locus. The maternal mutation was a deletion of bp 842-3 in exon 8, causing a shift in the reading frame. The paternal mutation was G+1A in the consensus donor splice site after exon 1; this splice site mutation would likely result in decreased mRNA. The likely consequence of these mutations is essentially a null phenotype.

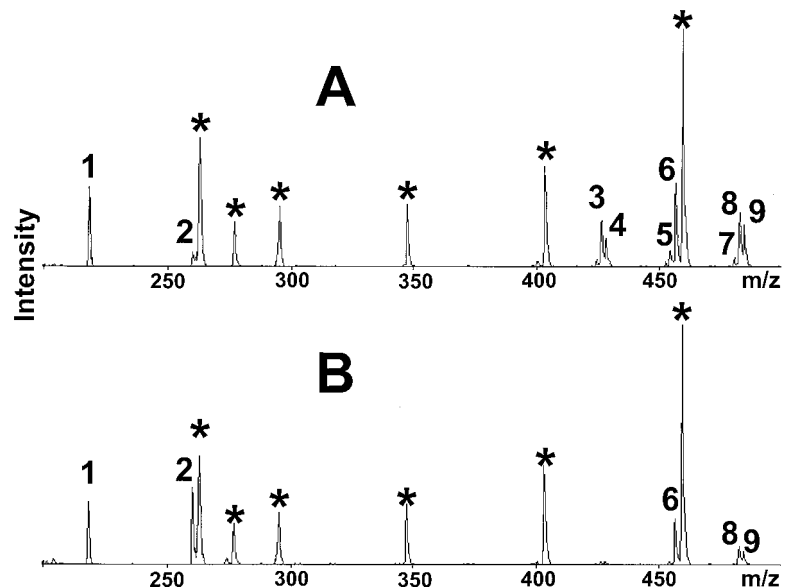
To determine whether this case could have been picked up by tandem mass spectrometry analysis at birth when the patient was asymptomatic, acylcarnitine analysis was performed on the patient's original newborn card (after obtaining parental consent, the original specimen was provided courtesy of Dr Kenneth Pass, Director, New York State Newborn Screening Program). The blood sample had been obtained at 1 week of age and stored at room temperature for 6 months and at -70°C thereafter for 18 months. Electrospray tandem mass spectrometry was performed according to a previously published method<sup>8</sup> using a LC-MS/MS API 2000 (Perkin-Elmer Sciex, Toronto, Ontario, Canada) operated in ion evaporation mode with the TurboIonSpray ionization probe source (Perkin-Elmer Sciex, Toronto, Ontario, Canada).

Figure 1 shows the acylcarnitine profile obtained from the patient's original newborn card analyzed 2 years after it was obtained. In comparison to a normal control (bottom profile), there was a significant accumulation of long chain acylcarnitine species, with a prominent peak of tetradecenoylcarnitine (C14:1), the most characteristic metabolic marker of VLCAD deficiency.<sup>9</sup> This profile would have likely been even more significant if it had been analyzed at the time of collection, yet 2 years later is sufficient to provide strong biochemical evidence of the underlying disorder.

### DISCUSSION

VLCAD was first discovered in 1992, and clinical experience with VLCAD deficiency has been accumulating rapidly.<sup>1,3,4,10-12</sup> Indeed, the patients origi-

**Fig 1.** Butyl-ester acylcarnitine profiles of blood spots from newborn screening cards obtained by precursor ion scanning (parent of  $m/z$  85) electrospray/tandem mass spectrometry. Top A): patient with VLCAD deficiency, analyzed 2 years after collection. Bottom B), normal control. The symbol (\*) corresponds to  $d_3$ -labeled internal standards (C2, C3, C4, C8, C12, and C16). Peak identification: 1) free carnitine ( $m/z$  218); 2) acetylcarnitine (C1,  $m/z$  260); 3) tetradecenoylcarnitine (C14:1,  $m/z$  426); 4) tetradecanoylcarnitine (C14:0,  $m/z$  428); 5) hexadecenoylcarnitine (C16:1  $m/z$  454); 6) palmitoylcarnitine (C16:0,  $m/z$  456); 7) linoleylcarnitine (C18:2,  $m/z$  480); 8) oleylcarnitine (C18:1,  $m/z$  482); and 9) stearoylcarnitine (C18:0,  $m/z$  484).



nally diagnosed with long chain acyl-CoA dehydrogenase deficiency suffer instead from VLCAD deficiency.<sup>11</sup> The phenotype of VLCAD deficiency is heterogeneous, ranging from catastrophic metabolic and cardiac failure in infancy to mild hypoketotic, hypoglycemia and exertional rhabdomyolysis in adults.<sup>2,3,7,13-15</sup> This case demonstrates that VLCAD deficiency could have been detected from the patient's own neonatal heel-stick sample. Most likely, a presymptomatic diagnosis would have avoided at least part of a lengthy and intensive prediagnosis hospitalization that had an estimated cost of \$400 000.

Although VLCAD is relatively rare, timely and correct diagnosis leads to dramatic recovery, so that detection by newborn screening could prevent the onset of arrhythmias, heart failure, metabolic insufficiency, and death.<sup>2,3,7</sup> Fatty acid oxidation defects, including VLCAD deficiency, may account for as many as 5% of sudden infant death patients.<sup>16</sup> Recent instrumentation advances have made automated tandem mass spectrometry of routine neonatal heel stick samples technically feasible.<sup>17-19</sup> Pilot studies have demonstrated an incidence of fatty acid oxidation defects, including short chain, medium chain, and very long chain acyl-CoA dehydrogenase deficiencies, of approximately 1/12 000.<sup>17</sup> As a result, cost-benefit ratios for this approach should be systematically examined.

#### REFERENCES

1. Aoyama T, Spurn M, Ushikubo S, et al. Purification of human very-long-chain acyl-coenzyme A dehydrogenase and characterization of its deficiency in seven patients. *J Clin Invest*. 1995;95:2465-2473
2. Bonnet D, Martin D, de Lonlay P, et al. Arrhythmias and conduction defects as presenting symptoms of fatty acid oxidation disorders in children. *Circulation*. 1999;100:2248-2253
3. Mathur A, Sims H, Gopalakrishnan D, et al. Molecular heterogeneity in very-long-chain acyl-coA dehydrogenase deficiency causing pediatric cardiomyopathy and sudden death. *Circulation*. 1999;99:1337-1343
4. Vianey-Saban C, Divry P, Brivet M, et al. Mitochondrial very-long-chain acyl-coenzyme A dehydrogenase deficiency: clinical characteristics and diagnostic considerations in 30 patients. *Clin Chim Acta*. 1998;269:43-62
5. Sluysmans T, Tuerlinckx D, Hubinont C, et al. Very long chain acyl-coenzyme A dehydrogenase deficiency in two siblings: evolution after prenatal diagnosis and prompt management. *J Pediatr*. 1996;131:444-446
6. Nada MA, Veaney-Saban C, Roe C, et al. Prenatal diagnosis of mitochondrial fatty acid oxidation defects. *Prenat Diagn*. 1996;16:117-124
7. Cox GF, Souri M, Aoyama T, et al. Reversal of severe hypertrophic cardiomyopathy and excellent neuropsychologic outcome in very-long-chain acyl-coenzyme A dehydrogenase deficiency. *J Pediatr*. 1998;133:247-253
8. Chace D, Hillman S, Van Hove J. Rapid diagnosis of MCAD deficiency: quantitative analysis of octanoylcarnitine and other acylcarnitines in newborn blood spots by tandem mass spectrometry. *Clin Chem*. 1997;43:2106-2113
9. Rashed M, Ozand P, Bucknall M, Little D. Diagnosis of inborn errors of metabolism from blood spots by acylcarnitines and amino acids profiling using automated electrospray tandem mass spectrometry. *Pediatr Res*. 1995;38:324-331
10. Uchida Y, Izai K, Orii T, Hashimoto T. Novel fatty acid B-oxidation enzymes in rat liver mitochondria. II. Purification and properties of enoyl-coenzyme A (CoA) hydratase/3-hydroxyacyl-CoA dehydrogenase/3-ketoacyl-CoA thiolase trifunctional protein. *J Biol Chem*. 1992;267:1034-1041
11. Yamaguchi S, Indo Y, Coates PM, Hashimoto T, Tanaka K. Identification of very-long-chain acyl-CoA dehydrogenase deficiency in three patients previously diagnosed with long-chain acyl-CoA dehydrogenase deficiency. *Pediatr Res*. 1993;34:111-113
12. Brown-Harrison MC, Nada MA, Sprecher H, et al. Very long chain acyl-CoA dehydrogenase deficiency: successful treatment of acute cardiomyopathy. *Biochem Mol Med*. 1996;58:59-65
13. Hug G, Daughery C, Vianey-Saban C, et al. Deficient activity of membrane bound very long chain acyl-coA dehydrogenase (VLCAD) in twin boys. Clinical, biochemical, and morphological observations [abstract]. *Pediatr Res*. 1993;35:36A
14. Merinero B, Pascual SIP, Perez-Cerda C, et al. Adolescent myopathic presentation in two sisters with very long-chain acyl-CoA dehydrogenase deficiency. *J Inherit Metab Dis*. 1999;22:802-810
15. Smelt AHM, Poorthuis BJHM, Onkenhout W, et al. Very long chain Acyl-Coenzyme A dehydrogenase deficiency with adult onset. *Ann Neurol*. 1997;43:540-544.
16. Boles RG, Buck EA, Blitzer MG, et al. Retrospective biochemical screening of fatty acid oxidation disorders in postmortem livers of 418 cases of sudden death in the first year of life. *J Pediatr*. 1998;132:924-933
17. Naylor EW, Chace DH. Automated mass spectrometry for mass newborn screening for disorders in fatty acid, organic acid, and amino acid metabolism. *J Child Neurol*. 1999;14:S4-S8
18. Millington DS, Terada N, Chace DH, et al. The role of tandem mass spectrometry in the diagnosis of fatty acid oxidation disorders. *Prog Clin Biol Res*. 1992;375:339-354
19. Charrow J, Goodman SI, McCabe ERG, Rinaldo P. Tandem mass spectrometry in newborn screening. *Genet Medicine*. 2000;2:267-269